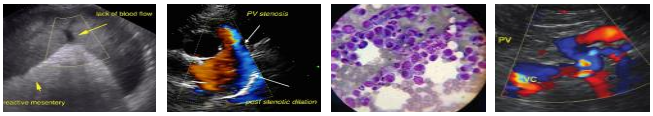

SonoPath.com
1-800-838-4268 info@sonopath.com

DATE

3/22/22

PERFORMED BY

Tom McNeill

INTERPRETED BY

Keith Blass, DVM, MS, DACVIM (Cardiology)

PATIENT

Sebastian Corridon

SPECIES

Feline

BREED

Maine Coon

SEX

MN

AGE

14 y

WEIGHT

13.8 lb

HOSPITAL NAME

SVS Imaging CT

REFERRING VET

Dr. Kvalheim

PRESENTING CLINICAL SIGNS

History: New murmur. BNP 222. Asymptomatic.

ECHOCARDIOGRAPHIC FINDINGS

2D, M-mode, and Doppler study.

Left atrial size is normal. Left ventricular wall thickness is normal. Left ventricular internal dimensions are normal. Left ventricular systolic function is hyperdynamic. The aorta and aortic valve are normal. Right atrial and right ventricular dimensions are normal. The tricuspid valve is normal. The pulmonary artery and pulmonic valve are normal. No pericardial effusion or cardiac masses are seen.

LA/Ao – 1.26
IVSd – 4.5 mm
LVPWd – 4.4 mm
LVIDd – 15.3 mm
LVIDs – 5.8 mm
FS – 62%
LVOT – 1.31 m/s
RVOT – 1.00 m/s

ASSESSMENT/RECOMMENDATIONS

Normal echocardiogram

This examination demonstrates no evidence of structural heart disease. As such, no reason for Sebastian's elevated BNP level is appreciated in the image set. It's possible that the elevation could be a false positive, though consideration should also be given to other causes of BNP elevations in cats, such as azotemia, hyperthyroidism, and systemic hypertension.

While no reason for Sebastian's murmur was identified, it's likely that his murmur is functional/innocent in nature, as no flow abnormalities that could result in the development of a pathologic murmur were appreciated in the image set.

No therapy is recommended is recommended based on this exam.

A recheck echocardiogram is recommended if the characteristics of Sebastian's murmur change, or if other new physical exam and/or clinical abnormalities suggestive of cardiac dysfunction develop.

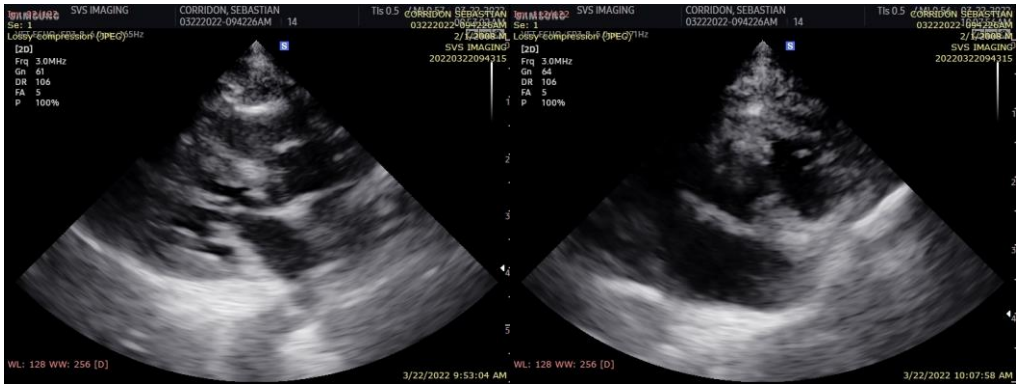

The information and recommendations provided are based on the images presented by the referring veterinarian. No evaluation can be communicated regarding pathology that was not

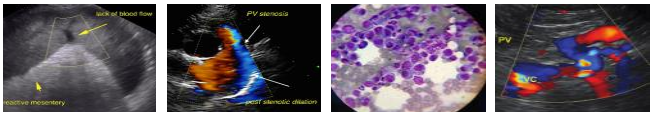

SonoPath.com
1-800-838-4268 info@sonopath.com

visible in the image/video clips provided.

Thank you for this referral. If the clinical or image interpretation does not parallel your findings or if I can be of any further assistance please contact me.

Keith Blass, DVM, MS, DACVIM (Cardiology)
KeithBlass@gmail.com
631-804-5754

DATE

3/22/22

PERFORMED BY

Tom McNeill

INTERPRETED BY

Keith Blass, DVM, MS, DACVIM (Cardiology)

PATIENT

Sebastian Corridon

SPECIES

Feline

BREED

Maine Coon

SEX

MN

AGE

14 y

WEIGHT

13.8 lb

HOSPITAL NAME

SVS Imaging CT

REFERRING VET

Dr. Kvalheim